

# THERMOACOUSTIC ASSESSMENT OF FATTY LIVER DISEASE - A CLINICAL FEASIBILITY STUDY

Jang Hwan Cho<sup>1</sup>, Michael Thornton<sup>1</sup>, Dr. Jing Gao<sup>3</sup>, Colby Adamson<sup>2</sup>, Idan Steinberg<sup>1</sup>

1. ENDRA Life Sciences inc, Ann Arbor, MI, USA

2. Ultrasound Research medical center, Rocky Vista University, Ivins, UT, USA



**ENDRA**  
LIFE SCIENCES

## INTRODUCTION

Quantitative ultrasound-based methods are the current standard of practice for point-of-care, non-invasive liver fat assessment. However, due to low penetration depth and confounding factors, invalid or poor-quality measurements are often encountered in large patients, or patients with liver fibrosis. In contrast to purely ultrasound-based approaches, thermoacoustic (TA) approaches are sensitive to tissue composition chemistry rather than acoustic scattering and/or attenuation, making TA measurements of liver fat content relatively insensitive to liver fibrosis or patient size.

## AIM

The Thermo-Acoustic Enhanced Ultrasound (TAEUS) Fatty Liver Imaging Probe (FLIP) is a hand-held, point-of-care device that quantitatively assesses liver fat and thus overcomes the drawbacks of conventional quantitative ultrasonic methods. This work describes results obtained from one clinical site, with two operators, comparing TAEUS-FLIP with MRI-PDFF to assess liver fat fraction.

## METHOD

45 volunteer study participants with suspected Non-Alcoholic Fatty Liver Disease (NAFLD) participated in a study that included B-mode ultrasound, obtained by trained sonographers, to determine the locations of the liver capsule and overlying tissue (muscle, fat, and skin), followed by a TAEUS FLIP procedure consisting of 10 to 30 measurements. Finally, MRI-PDFF measurements were obtained to measure the subjects' true liver fat fraction. Thermoacoustic signals matching liver and fat/muscle anatomy (as derived from B-mode ultrasound) were used to estimate liver tissue conductivity, a tissue property closely related to liver fat fraction.

## RESULTS

One subject had a failed TAEUS FLIP exam, and 5 subjects with subcutaneous fat <6mm were excluded from the results. The 45 remaining study participant exams included 4 cases of fibrosis (confirmed by elastography). The BMI of study participants was in the range of 24 to 45, with 14 participant exams having a BMI of 35, or greater.

Figure 2 shows the median estimated liver tissue conductivity for each participant exam compared to MRI-PDFF. The two methods are strongly correlated, with a correlation of **R<sup>2</sup>=0.75**.

The TAEUS FLIP method has a **sensitivity of 0.95 and specificity of 0.77 (AUROC = 0.88)**, and a **PPV of 0.75 and NPV of 0.95** in detecting the presence of fatty liver disease at a threshold of 6% MRI-PDFF.

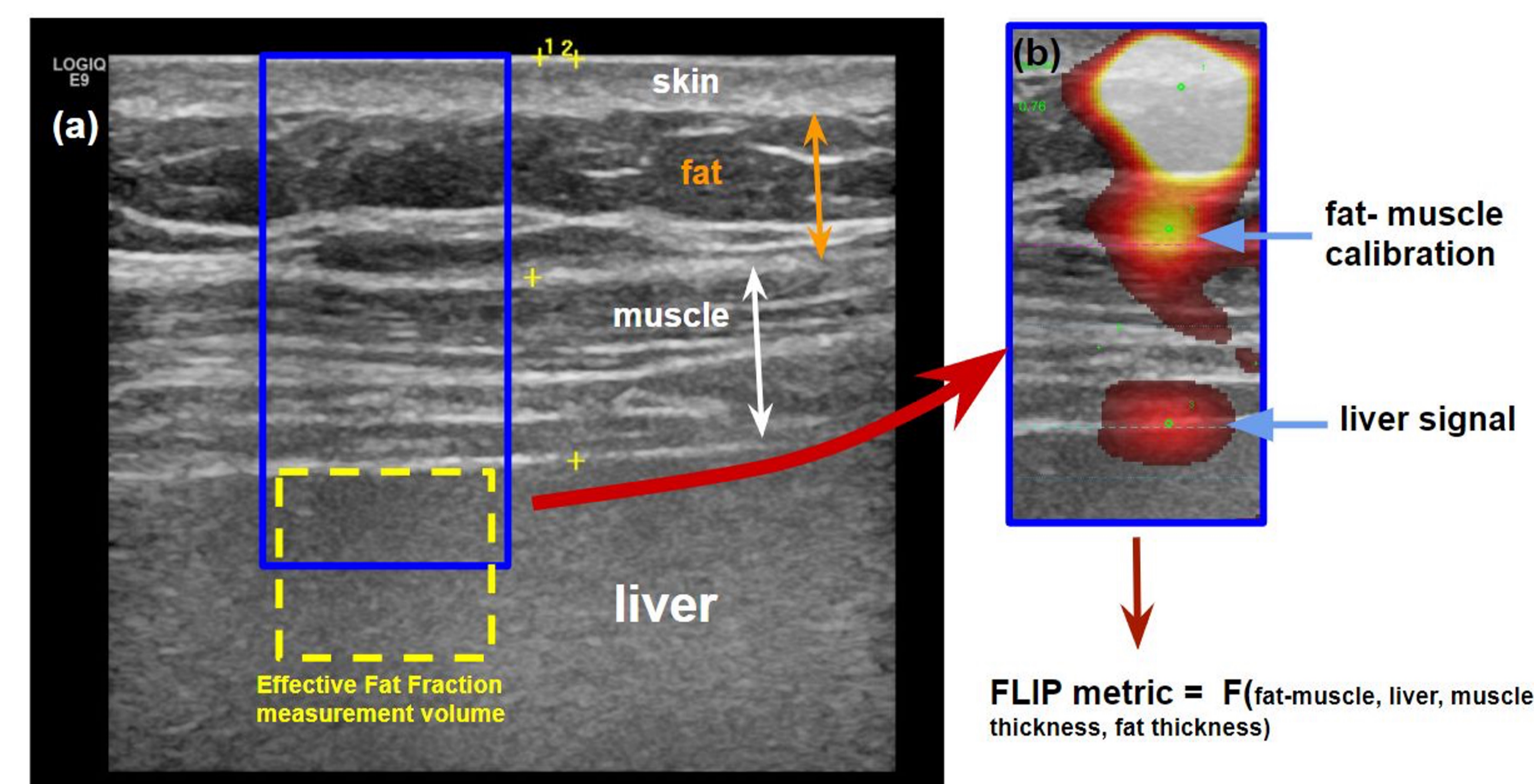


Fig. 1 Conventional ultrasound images obtained with a linear probe are able to delineate the relevant tissue structures in measurement location (skin, subcutaneous fat, intercostal muscle, and liver). The liver tissue measurement is obtained from a 16mm cylindrical region below the liver capsule as shown in (a) with the yellow dashed box. The thermoacoustic calibration and liver signals are shown in (b) overlaid onto the conventional ultrasound image. The FLIP metric incorporates acquired thermoacoustic signals and patient specific tissue depths.

## MRI –PDFF vs thermoacoustic estimate of liver fat fraction (FLIP metric)

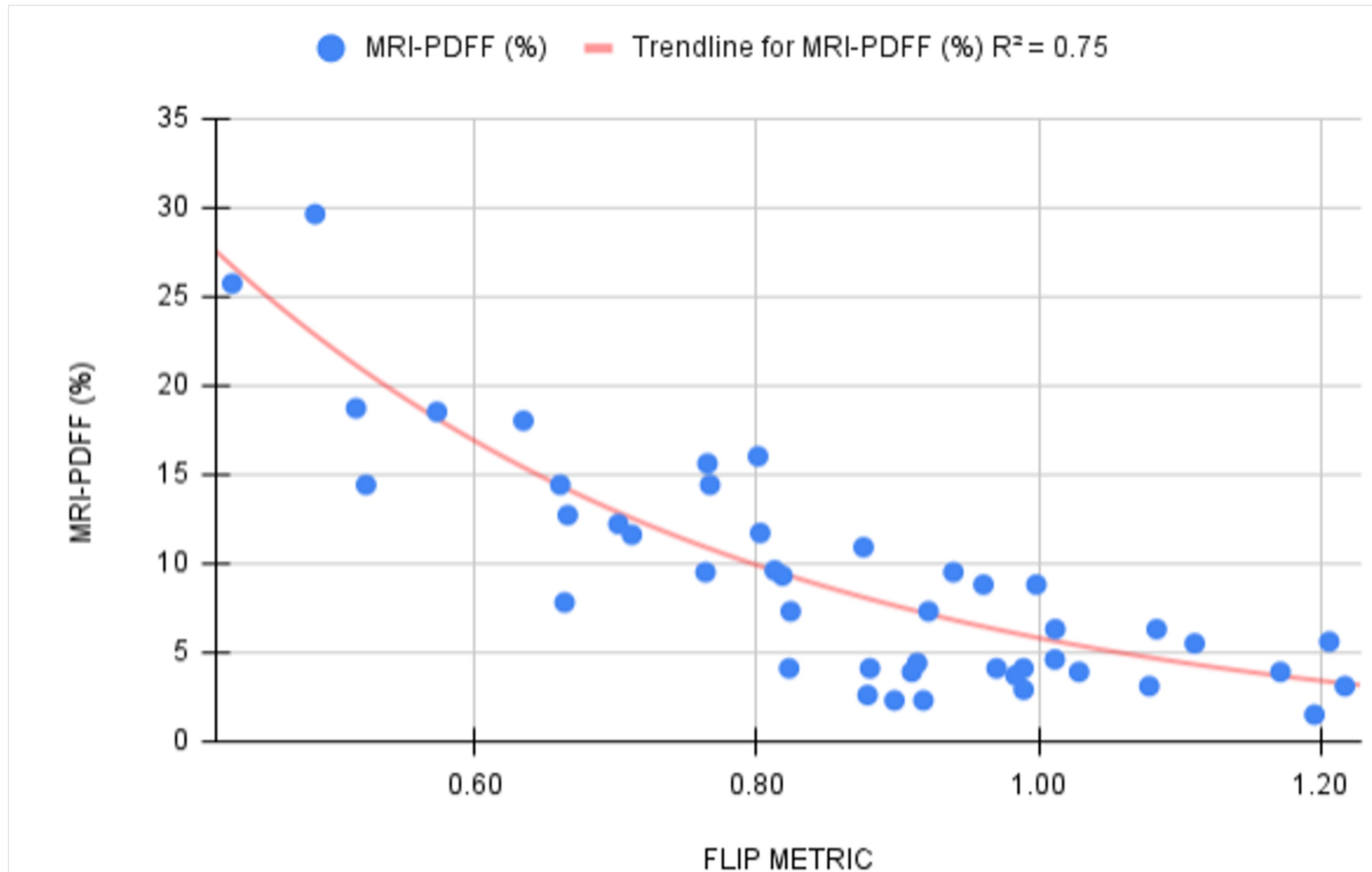


Fig. 2 The median FLIP metric for each of the 45 study participant exams is plotted vs. their MRI-PDFF score.

## CONCLUSIONS

This liver fat fraction feasibility study compares TAEUS-FLIP to MRI-PDFF and provides insight into the potential of thermoacoustic methods to assess liver fat content, similar to MRI-PDFF, at the point of care.

Unlike conventional quantitative ultrasound methods, the thermoacoustic approach has demonstrated the potential to obtain estimates of liver fat fraction in individuals with high BMI (45), and those with confirmed liver fibrosis.

## REFERENCES

Daniel R. Bauer; Xiong Wang; Jeff Vollen; Hao Xin; Russell S. Witte, **Spectroscopic thermoacoustic imaging of water and fat composition.** *Appl. Phys. Lett.* 101, 033705 (2012) <https://doi.org/10.1063/1.4737414>

Yu-tian Cao, et al. **Accuracy of controlled attenuation parameter (CAP) and liver stiffness measurement (LSM) for assessing steatosis and fibrosis in non-alcoholic fatty liver disease: A systematic review and meta-analysis** VOLUME 51, 101547, SEPTEMBER 2022

Olumide Ogunlade and Paul Beard, **Exogenous contrast agents for thermoacoustic imaging: An investigation into the underlying sources of contrast** *Medical Physics* 42, 170 (2015); doi: 10.1118/1.4903277

## ACKNOWLEDGEMENTS

The authors would like to thank Nick Marshall, MRI Team, Dixie Regional Medical, St. George, UT, for assistance in obtaining MRI-PDFF image sequences for participants in this study.

## CONTACT INFORMATION

Email: [jcho@endrainc.com](mailto:jcho@endrainc.com); [mthornton@endrainc.com](mailto:mthornton@endrainc.com)